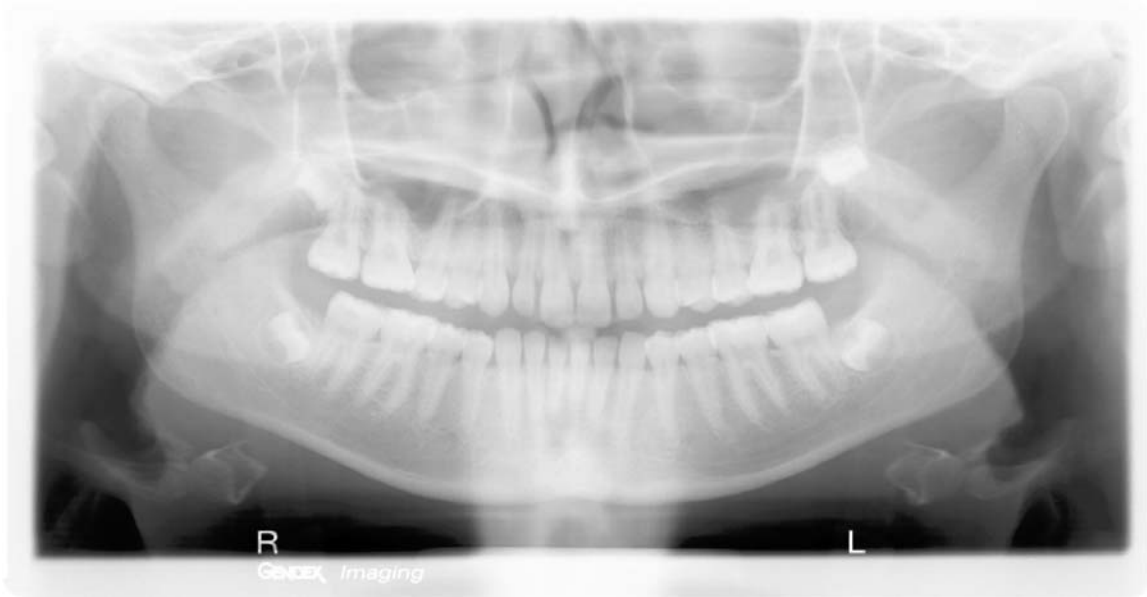
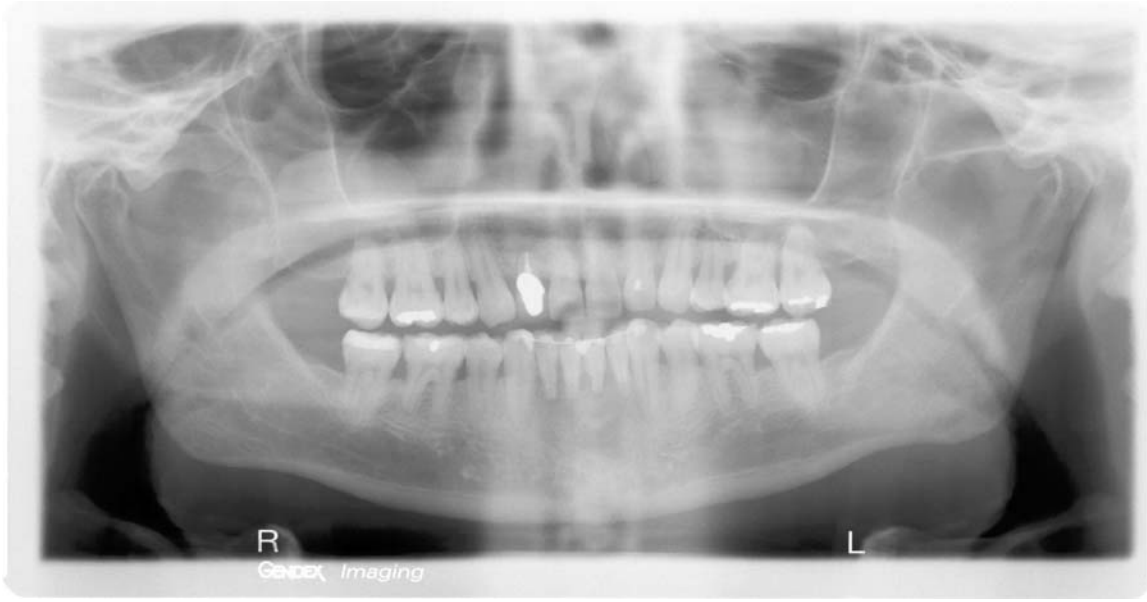

Amy Nieves, RDH
Study guide for students for National Boards
Panograph xrays
© 2004 Amy Nieves, RDH
www.amyrdh.com

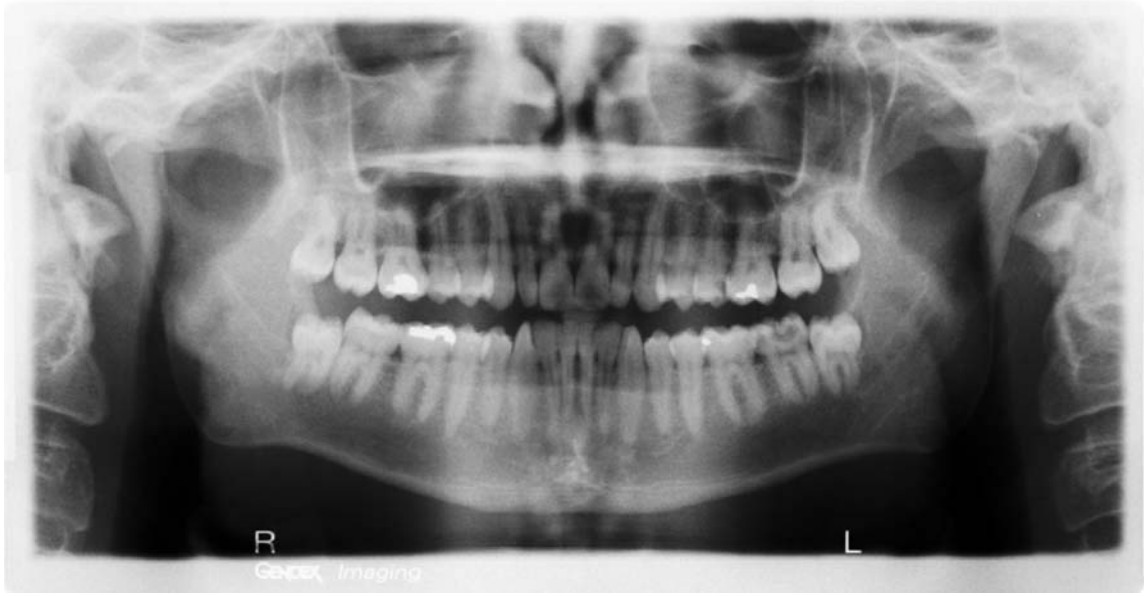


1. Locate the middle cranial fossa
2. Locate the orbit
3. Locate the Zygomatic process
4. Locate the Palate
5. Locate the styloid process
6. Locate the septa in maxillary sinus
7. Locate the maxillary tuberosity
8. Locate the external oblique line
9. Locate the angle of mandible
10. Locate the hyoid bone
11. Locate the glenoid fossa
12. Locate the articular eminence
13. Locate the mandibular condyle
14. Locate the vertebra
15. Locate the coronoid process
16. Locate the pterygoid process
17. Locate the maxillary sinus
18. Locate the ear lobe
19. Locate the mandibular canal
20. Locate the mental foramen
21. What is the range of the age of this patient?



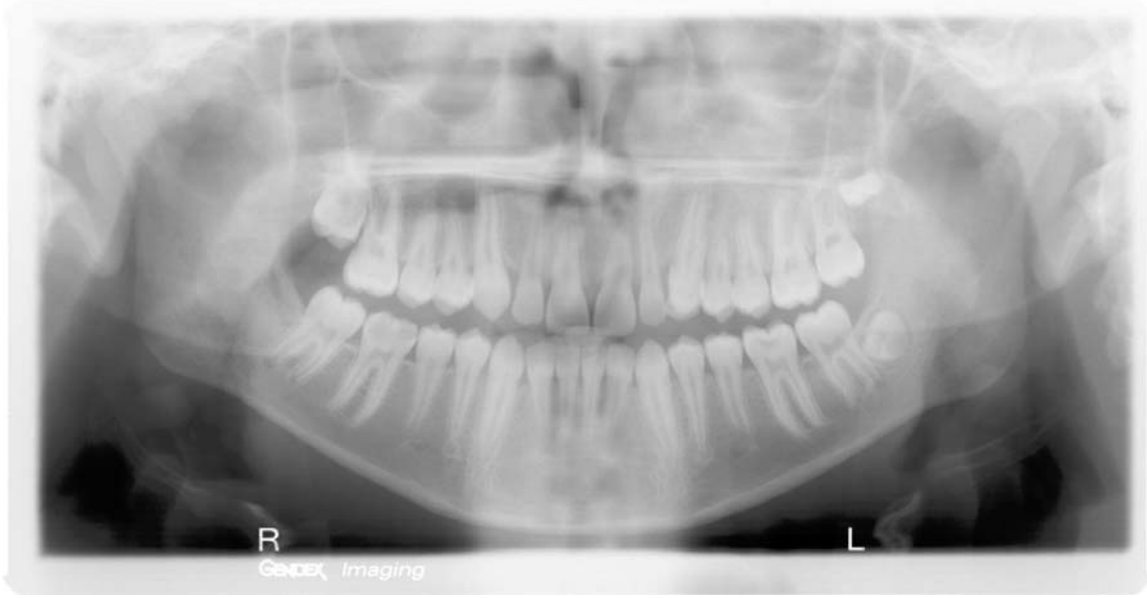22. Locate the middle cranial fossa
23. Locate the orbit
24. Locate the Zygomatic process
25. Locate the Palate
26. Locate the styloid process
27. Locate the septa in maxillary sinus
28. Locate the maxillary tuberosity
29. Locate the external oblique line
30. Locate the angle of mandible
31. Locate the hyoid bone
32. Locate the glenoid fossa
33. Locate the articular eminence
34. Locate the mandibular condyle
35. Locate the vertebra
36. Locate the coronoid process
37. Locate the pterygoid process
38. Locate the maxillary sinus
39. Locate the ear lobe
40. Locate the mandibular canal
41. Locate the mental foramen

Amy Nieves, RDH
Study guide for students for National Boards
Panograph xrays
© 2004 Amy Nieves, RDH
www.amyrdh.com



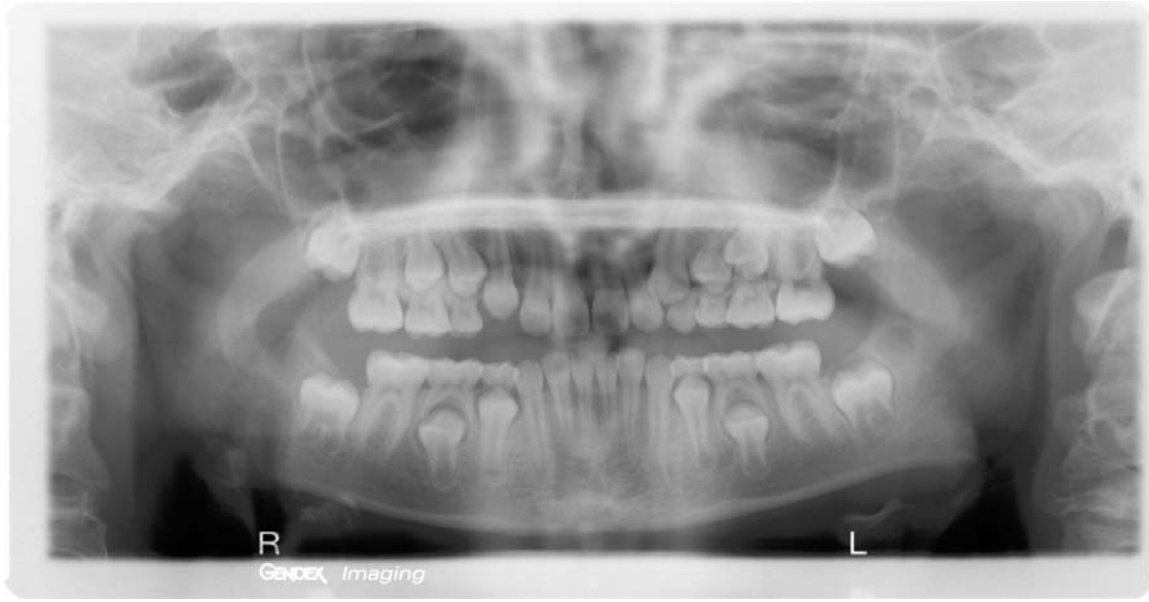42. Locate the middle cranial fossa
43. Locate the orbit
44. Locate the Zygomatic process
45. Locate the Palate
46. Locate the styloid process
47. Locate the septa in maxillary sinus
48. Locate the maxillary tuberosity
49. Locate the external oblique line
50. Locate the angle of mandible
51. Locate the hyoid bone
52. Locate the glenoid fossa
53. Locate the articular eminence
54. Locate the mandibular condyle
55. Locate the vertebra
56. Locate the coronoid process
57. Locate the pterygoid process
58. Locate the maxillary sinus
59. Locate the ear lobe
60. Locate the mandibular canal
61. Locate the mental foramen
62. What is the approximate age of this patient?

*Amy Nieves, RDH
Study guide for students for National Boards
Panograph xrays
© 2004 Amy Nieves, RDH
www.amyrdh.com*



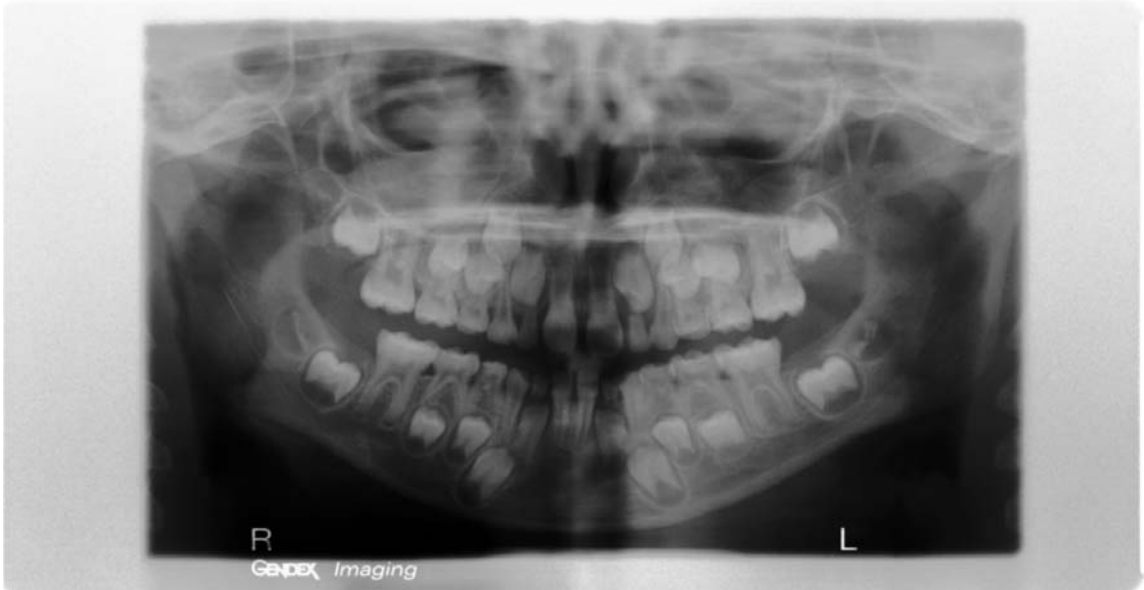63. Locate the middle cranial fossa
64. Locate the orbit
65. Locate the Zygomatic process
66. Locate the Palate
67. Locate the styloid process
68. Locate the septa in maxillary sinus
69. Locate the maxillary tuberosity
70. Locate the external oblique line
71. Locate the angle of mandible
72. Locate the hyoid bone
73. Locate the glenoid fossa
74. Locate the articular eminence
75. Locate the mandibular condyle
76. Locate the vertebra
77. Locate the coronoid process
78. Locate the pterygoid process
79. Locate the maxillary sinus
80. Locate the ear lobe
81. Locate the mandibular canal
82. Locate the mental foramen
83. What is the approximate age of this patient?

Amy Nieves, RDH
Study guide for students for National Boards
Panograph xrays
© 2004 Amy Nieves, RDH
www.amyrdh.com



84. Locate the middle cranial fossa
85. Locate the orbit
86. Locate the Zygomatic process
87. Locate the Palate
88. Locate the styloid process
89. Locate the septa in maxillary sinus
90. Locate the maxillary tuberosity
91. Locate the external oblique line
92. Locate the angle of mandible
93. Locate the hyoid bone
94. Locate the glenoid fossa
95. Locate the articular eminence
96. Locate the mandibular condyle
97. Locate the vertebra
98. Locate the coronoid process
99. Locate the pterygoid process
100. Locate the maxillary sinus
101. Locate the ear lobe
102. Locate the mandibular canal
103. Locate the mental foramen
104. What is the approximate age of this patient?

Amy Nieves, RDH
Study guide for students for National Boards
Panograph xrays
© 2004 Amy Nieves, RDH
www.amyrdh.com



105. Locate the middle cranial fossa
106. Locate the orbit
107. Locate the Zygomatic process
108. Locate the Palate
109. Locate the styloid process
110. Locate the septa in maxillary sinus
111. Locate the maxillary tuberosity
112. Locate the external oblique line
113. Locate the angle of mandible
114. Locate the hyoid bone
115. Locate the glenoid fossa
116. Locate the articular eminence
117. Locate the mandibular condyle
118. Locate the vertebra
119. Locate the coronoid process
120. Locate the pterygoid process
121. Locate the maxillary sinus
122. Locate the ear lobe
123. Locate the mandibular canal
124. Locate the mental foramen
125. What is the approximate age of this patient?
126. What do you see behind the mand. 2nd molars?

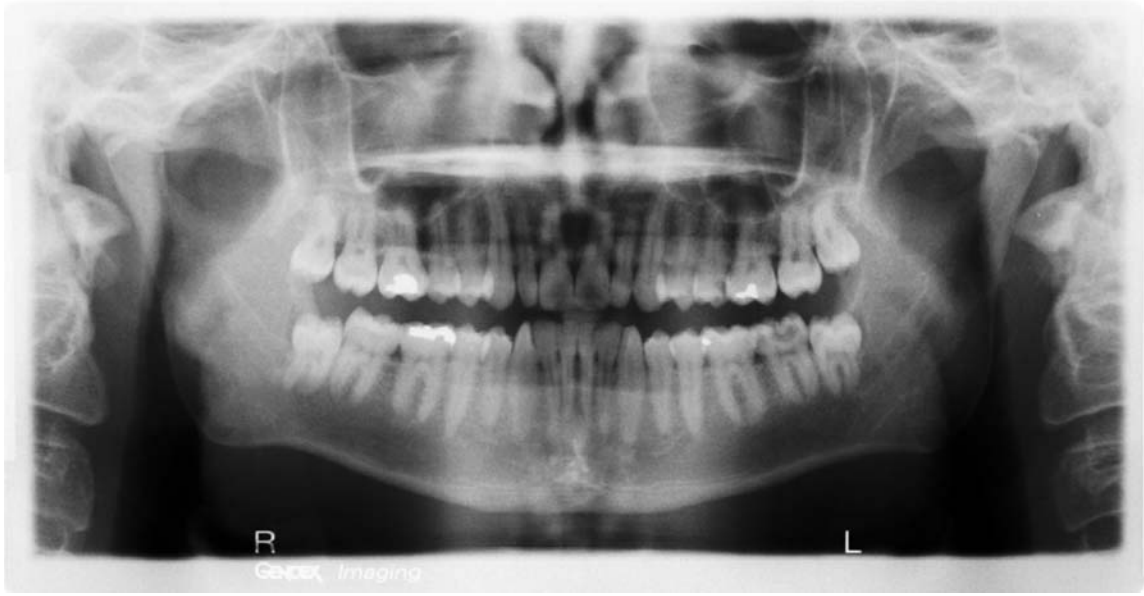
Amy Nieves, RDH

Study guide for students for National Boards

Panograph xrays

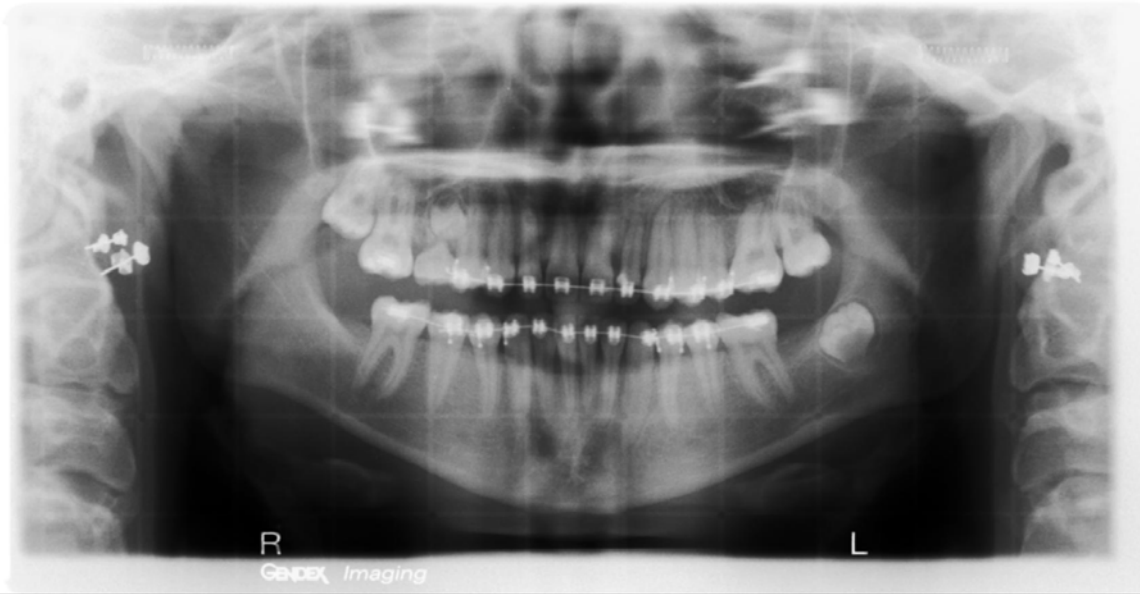© 2004 Amy Nieves, RDH

www.amyrdh.com



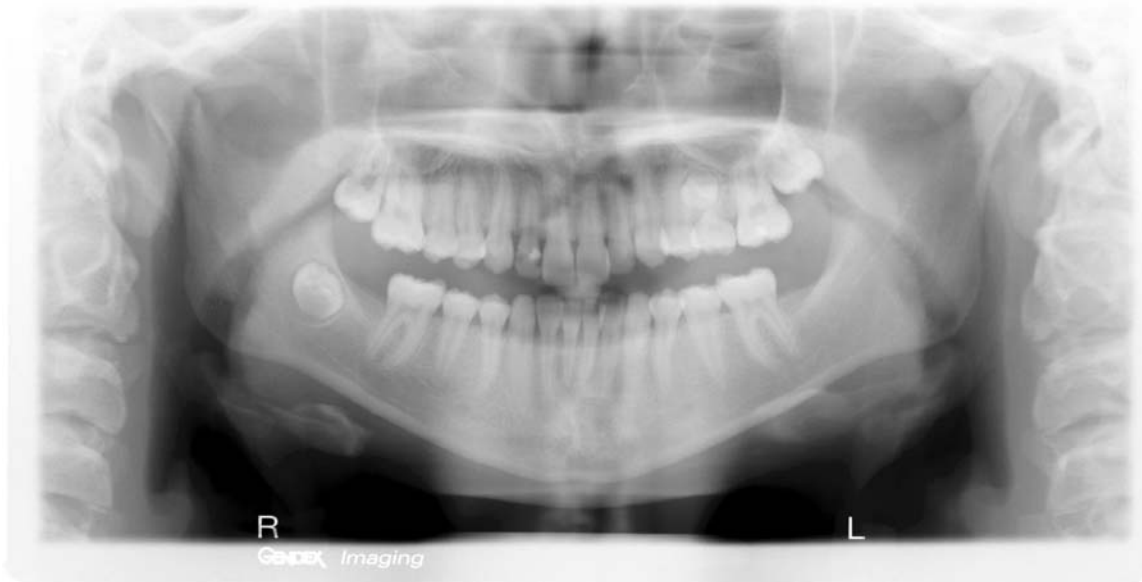127. Locate the middle cranial fossa
128. Locate the orbit
129. Locate the Zygomatic process
130. Locate the Palate
131. Locate the styloid process
132. Locate the septa in maxillary sinus
133. Locate the maxillary tuberosity
134. Locate the external oblique line
135. Locate the angle of mandible
136. Locate the hyoid bone
137. Locate the glenoid fossa
138. Locate the articular eminence
139. Locate the mandibular condyle
140. Locate the vertebra
141. Locate the coronoid process
142. Locate the pterygoid process
143. Locate the maxillary sinus
144. Locate the ear lobe
145. Locate the mandibular canal
146. Locate the mental foramen

*Amy Nieves, RDH
Study guide for students for National Boards
Panograph xrays
© 2004 Amy Nieves, RDH
www.amyrdh.com*



147. Locate the middle cranial fossa
148. Locate the orbit
149. Locate the Zygomatic process
150. Locate the Palate
151. Locate the styloid process
152. Locate the septa in maxillary sinus
153. Locate the maxillary tuberosity
154. Locate the external oblique line
155. Locate the angle of mandible
156. Locate the hyoid bone
157. Locate the glenoid fossa
158. Locate the articular eminence
159. Locate the mandibular condyle
160. Locate the vertebra
161. Locate the coronoid process
162. Locate the pterygoid process
163. Locate the maxillary sinus
164. Locate the ear lobe
165. Locate the mandibular canal
166. Locate the mental foramen

Amy Nieves, RDH
Study guide for students for National Boards
Panograph xrays
© 2004 Amy Nieves, RDH
www.amyrdh.com



167. Locate the middle cranial fossa
168. Locate the orbit
169. Locate the Zygomatic process
170. Locate the Palate
171. Locate the styloid process
172. Locate the septa in maxillary sinus
173. Locate the maxillary tuberosity
174. Locate the external oblique line
175. Locate the angle of mandible
176. Locate the hyoid bone
177. Locate the glenoid fossa
178. Locate the articular eminence
179. Locate the mandibular condyle
180. Locate the vertebra
181. Locate the coronoid process
182. Locate the pterygoid process
183. Locate the maxillary sinus
184. Locate the ear lobe
185. Locate the mandibular canal
186. Locate the mental foramen

*Amy Nieves, RDH
Study guide for students for National Boards
Panograph xrays
© 2004 Amy Nieves, RDH
www.amyrdh.com*